

Do Not Forget about Tuberculosis- Intestinal Tuberculosis or Crohn's Disease- A Diagnostic Challenge

Avgustina Georgieva^{1,2,6*}, Antonia Atanassova^{1,3,6}, Denitsa Dukova^{1,2,6}, Milko Mirchev^{1,2,6}, Maria Tzaneva^{4,6}, Svetomir Chakarov^{5,6}

¹Clinic of Gastroenterology, "St. Marina" University Hospital of Varna

²Second Department of Internal Diseases

³Department of Anatomy and Cell Biology

⁴Department of General and Clinical Pathology, Forensic Medicine and Deontology, "St. Marina" University Hospital of Varna

⁵Department of Diagnostics Imaging and Radiotherapy, "St. Marina" University Hospital of Varna

⁶Medical University – Varna, Bulgaria

***Corresponding author:** Avgustina Chavdarova Georgieva MD, PhD, Varna, Hristo Smirnenski Bul., floor 11, Clinic of Gastroenterology, Multiprofile University Hospital for Active Treatment "Sveta Marina", city of Varna, Bulgaria, Tel: +19177923454; E mail: mailto:avgustina_dobрева@yahoo.com

Abstract

Background & Aims: Very often the differential diagnosis between Crohn's disease and ITB is difficult because the two diseases have similar clinical picture, endoscopic and histological findings, as well as imaging changes.

Case report: We present a case of 24-year-old male with intestinal tuberculosis initially suspected to be Crohn's disease. Endoscopy and CT findings suggested probable Crohn's disease and in a differential diagnosis we thought about ITB, but the Mantoux test and T-SPOT.TB test were negative. Due to the chronic cough and subfebrile temperature, an X-ray of the lung was performed, and the finding was very characteristic of lung tuberculosis. It was followed by positive bronchoalveolar lavage fluid (BALF) smear microscopy for Mycobacterium tuberculosis (MbT) and by a positive microbiological culture. In the biopsy of the small intestine material, an outbreak is detected of epithelioid cell granuloma with caseous necrosis in the centre, as well as Langhans giant cells – morphological criteria of intestinal tuberculosis.

The patient completed 9-month tuberculosis treatment, followed by a microbiologically achieved conversion to bacillus separation. Six months after stopping the tuberculostatic treatment the patient has normal lab tests, and the ileocolonoscopy did not reveal mucosal abnormalities.

Conclusion: In case of suspected Crohn's disease in clinical practice, intestinal tuberculosis should always be excluded by a set of diagnostic methods, even if it is not an immunosuppressed or immunocompromised patient. Abdominal tuberculosis, in particular intestinal (ITB), is still a diagnostic challenge for clinicians.

Key words: Tuberculosis; Extrapulmonary; Gastrointestinal tract; Crohn's disease

Background

Abdominal tuberculosis, in particular intestinal (ITB), is still a diagnostic challenge for clinicians. Very often the differential diagnosis between Crohn's disease and ITB is difficult because the two diseases have similar clinical picture, endoscopic and histological findings, as well as imaging changes^[1,2].

Despite the active worldwide prevention of the infection, which aims to eradicate it, there is still high TB incidence due to population migration and increasing incidence of diseases requiring immunosuppressive treatment^[3,4].

We present a case of intestinal tuberculosis initially suspected to be Crohn's disease.

Received date: October 15, 2019

Accepted date: October 29, 2019

Publish date: November 5, 2019

Citation: Georgieva, A., et al. Do Not Forget about Tuberculosis- Intestinal Tuberculosis or Crohn's Disease- A Diagnostic Challenge (2019) J Gastrointest Disord Liver Func 5(1) 28-32.

Copy Rights: © 2019 Georgieva, A. This is an Open access article distributed under the terms of Creative Commons Attribution 4.0 International License.

Case report

24-year-old male, non-smoker, without prior medical disorders, HIV- negative, referred to a gastroenterology clinic due to clinical and endoscopic suspicion of IBD - ulcerative colitis.

On admission he has a 12-month history of constant abdominal pain, chronic diarrhoea / 7-8 bowel movements per day/, weakness, subfebrile temperature and an episode of hematochesia. In one year he lost 13 kilograms. Has been coughing for approximately 6 months with insignificant expectoration. No chronic use of medications.

Physical examination revealed: pale skin and visible mucous membranes, pain at palpation in the right lower abdominal quadrant. The patient has BMI of 15.6 (height - 170 cm; weight - 45 kg).

Laboratory data during admission revealed: leucocytosis [total leukocytes: 19.6×10^9 (normal values $3.79 - 10.33 \times 10^9$), anaemia [Haemoglobin: 114 g / l (normal values 135 – 172 g / l)], thrombocytosis [platelets: 954×10^9 (normal values 140 – 440 $\times 10^9$), elevated CRP levels: 153 mg/l (normal values ≤ 5 mg/l), low serum iron levels: 2.5 $\mu\text{mol} / \text{L}$ (normal values 11.6 - 31.3 $\mu\text{mol} / \text{L}$), low levels of vitamin B12: 106 pmol / L (normal values 156- 672 pmol / L), cholestasis without jaundice [GGT 115 U / L (normal values 0– 73 U / L) and ALP: 210 U / L (normal values 45- 129 U / L)].

Stool samples were negative for enteropathogens: E. coli, Salmonella, Shigella, Campylobacter jejuni, Yersinia enterocolitica and Cl. Difficile toxin A / B.

The performed transabdominal ultrasonography of gastrointestinal tract found multiple slightly dilated fluid-filled small bowel loops with pendulous peristalsis. The colon descendens was shown as bowel wall thickening up to 7-8mm. To the right of the urinary bladder there was a bowel loop with 7 mm thickened bowel wall.

Ileocolonoscopy revealed a Bauhin's valve insufficiency, with oedematous mucosa and hyperaemia.

From the cecum in distal direction throughout the colon there were multiple ulcers with marked oedema of the edges, in places covered with fibrin deposits as well and inflammatory polyps. The mucosa surrounding the ulcers appears normal with a preserved vascular pattern.

A Computed tomography (CT) enterography was performed. Mucosal hyper-enhancement was found along 4cm of the terminal ileum. It showed a circumferential wall thickening of the cecum and ascending colon up to 5mm, with 10cm length. (Figure 1) Similar changes are observed in colon descendens, which has a wall thickness up to 5 mm, with length of approximately 12 cm. There is marked contrast of the mucous layer as well as enlarged abdominal lymph nodes.

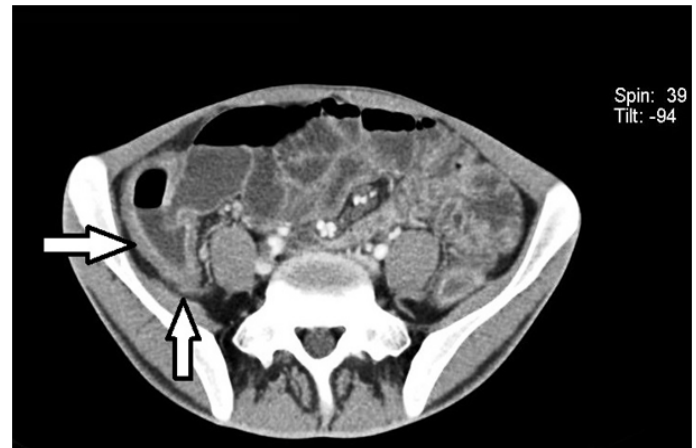

Figure 1: A circumferential wall thickening of the cecum colon up to 5mm (White arrows)

Endoscopy and CT findings suggested probable Crohn's disease - A2L3B1 and in a differential diagnosis we thought about ITB. This is why we performed tuberculin skin test (Mantoux test) - 0 mm; Interferon gamma release assays (IGRA) test- T-SPOT.TB test - negative. Due to the chronic cough and subfebrile temperature, an X-ray of the lung was performed.

Chest X-ray presented patchy alveolar infiltrates in the right upper, left middle and left upper lung field. (Figure 2)

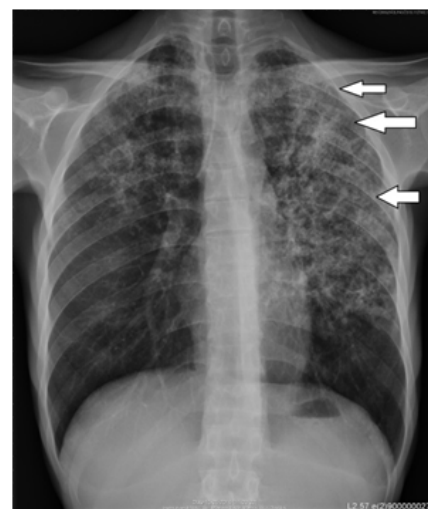


Figure 2: Chest X-ray with multiple bilateral variable-sized confluent lung nodules

Chest CT showed multiple bilateral variable-sized confluent lung nodules more pronounced at the apical portion of the left upper lobes - 1st, 2nd, 3rd, and 6th segments and less pronounced in the 4th and 5th segments, and discreetly in the basal segments of the lower lobes. A CT scan also showed enlarged paratracheal, aortopulmonary and hilar lymph nodes.

Fibrobronchoscopy was performed with bronchoalveolar lavage. Positive Broncho Alveolar Lavage Fluid (BALF) smear microscopy for Mycobacterium tuberculosis (MbT) was followed by positive microbiological culture.

Histopathological examination of the biopsy of the colon shows dilated crypts filled with detritus and neutrophils, lymphoplasmacytic inflammatory infiltration into the chorion

with neutrophils inclusions. In the small intestine material, an outbreak is detected of epithelioid cell granuloma with caseous necrosis in the centre, as well as Langhans giant cells – morphological criteria of intestinal tuberculosis. (Figure 3 A/B).

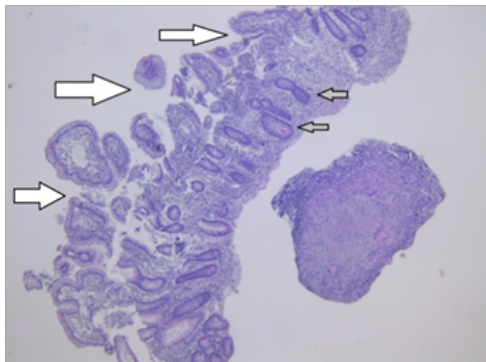


Figure 3/A: Small intestine biopsy with deformed villi (white arrow) and dilation of the lymph vessels (grey arrow) / H & E $\times 100$.

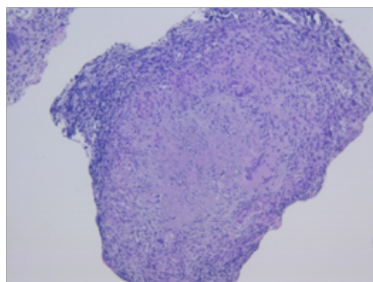


Figure 3/B: Granuloma composed of central caseation surrounded from epithelioid cells and multiple Langhans giant cells/ H & E $\times 200$.

Based on the conducted tests, it was believed to be infiltrative pulmonary tuberculosis with extra-pulmonary distribution and terminal ileum involvement of the lung with extra-pulmonary distribution and involvement of the small intestine.

According to the national regulation rules of treatment the patient completed 9-month fixed-dose combinations of drugs: Isoniazid + Tubocin + Pyrazinamide + Capreomycin for one month; HRZE (Isoniazid + Rifampin+ Pyrazinamide + Ethambutol) for two months; Isoniazid + Tubocin + Ethambutol for three months; Isoniazid + Tubocin for two months.

At the end of therapy there was a microbiologically achieved conversion to bacillus separation.

Six months after stopping the tuberculostatic treatment the patient has a BMI of 20.8 (height - 170 cm; weight – 60 kg), no abdominal pain, no diarrhoea, no fever.

Laboratory examination: total leukocytes: 8.09×10^9 (normal values $3.79 - 10.33 \times 10^9$), Hemoglobin: 166 g / l (normal values 135 – 172 g / l), platelets: 279×10^9 (normal values 140 – 440 $\times 10^9$), CRP levels: 0.66 mg / l (normal values ≤ 5 mg / l), serum iron levels: 15.7 $\mu\text{mol} / \text{L}$ (normal values 11.6 - 31.3 $\mu\text{mol} / \text{L}$), vitamin B12 levels : 198 pmol / L (normal values 156- 672 pmol / L), normal liver enzymes.

The follow-up ileocolonoscopy did not reveal mucosal abnormalities.

Chest CT determined a reduction in the activity of the outbreak.

Discussion

Patient's complaints on admission: chronically persisting abdominal pain, chronic diarrhoea, astheno-adyamic syndrome, subfebrility, low weight, leucocytosis, high CRP levels, anaemia, imaging data of oedema of the wall of the terminal ileum necessitate another ileocolonoscopy.

The endoscopic changes of the terminal ileum and Bauhin's valve, with negative IGRA test (T.SPOT.BT) and negative Mantoux, initially led to a Crohn's disease diagnosis.

The mild persistent cough, fever, anaemia, weakness and weight loss and lung graph data suggest pulmonary tuberculosis. A bronchoalveolar lavage with a subsequent direct bacterioscopy confirms that he has pulmonary tuberculosis. The morphological examination of biopsies taken from the terminal ileum shows haematogenous disseminated TB with involvement of the small intestine.

Data from literature indicates that about a quarter of abdominal tuberculosis cases develop together with pulmonary tuberculosis^[5].

In our patient, the initial clinical focus was on the chronic diarrhoea and abdominal pain with endoscopic changes that indicate IBD. Many authors point out the difficulty of differential diagnosis between macroscopic changes in CD and ITB. Although tuberculosis can also affect all parts of the gastrointestinal tract, in most cases, predilection falls on the terminal ileum, ileocecal connection, and caecum^[6,7,8,9].

Laboratory changes are nonspecific and indicate an inflammatory process. A number of authors have emphasised that the combination of non-specific laboratory changes and interferon gamma levels in IGRA tests help with the diagnosis^[10,11,12].

However, in our patient's case, the skin tuberculin sample and IGRA test were negative; therefore the clinical suspicion was in the direction of IBD.

Some authors describe in the diagnostic algorithm that the computed tomography of the abdomen and small intestine as a crucial diagnostic method for the confirmation of extra-pulmonary tuberculosis^[13].

The changes in our patient detected by CT enterography are small and non-specific. The direct bacterioscopy of BAL and small intestine morphology were crucial for the diagnosis of infiltrative pneumonic tuberculosis of the lung with extra-pulmonary spreading and involvement of the small intestine.

The post-treatment follow-up of TBC by cross-sectional imaging is given importance in the literature^[14], whereas we preferred to combine these methods with endoscopic tracing and morphological evaluation.

Conclusion

Tuberculosis is considered a rare disease in developed countries. Despite a worldwide decline in tuberculosis prevalence of around 2% per year, the disease remains in the top 10 as a cause of death, affecting all regions and age groups. The fastest rate of decline is seen in Europe with 11% per year (for a period of 5 years)^[3].

At the same time, there is a worldwide increase in the

incidence of IBD (Crohn's disease and ulcerative colitis).

The clinical, laboratory, imaging and endoscopic findings in Crohn's disease and intestinal tuberculosis are similar, and none of these methods on its own can lead to a diagnosis. Even the histomorphological presence of granulomas with caseous necrosis, which is considered a pathognomonic finding, may not be discovered in the early stages of intestinal tuberculosis.

Therefore, the gastroenterologist who is diagnosing Crohn's disease for the first time must exclude a number of diseases, including intestinal tuberculosis. This process is sometimes difficult and requires clinical experience, differential diagnostic thinking, and remains a challenge.

Conflicts of interest

None to declare.

References

- Singh, G., Krause, J.R., Breitfeld, V. Bone marrow examination: for metastatic tumor: aspirate and biopsy. 1977 *Cancer*. 40(5): 2317–2321.
[PubMed](#) | [Crossref](#) | [Others](#)
- Rhee, J., Han, S.W., Oh, D.Y., et al. Clinicopathologic features and clinical outcomes of gastric cancer that initially presents with disseminated intravascular coagulation: a retrospective study. (2010) *J Gastroenterol Hepatol* 25(9): 1537–1542.
[PubMed](#) | [Crossref](#) | [Others](#)
- Ringenberg, Q.S., Doll, D.C., Yarbrow, J.W., et al. Tumors of unknown origin in the bone marrow. (1986) *Arch Intern Med* 146(10): 2027–2028.
[PubMed](#) | [Crossref](#) | [Others](#)
- Sugarbaker, E.V., Thornthwaite, J., Ketcham, A.S. Inhibitory effect of a primary tumor on metastasis. In: Delrio G, Brachet J, editors. *Progress in Cancer Research and Therapy*. (1997) 227-240.
[PubMed](#) | [Crossref](#) | [Others](#)
- Jarcho, S. Diffusely infiltrative carcinoma. A hitherto undescribed correlation of several varieties of tumor metastasis. (1936) *Arch Pathol* 22: 674-696.
[PubMed](#) | [Crossref](#) | [Others](#)
- Brain, M.C., Azzopardi, J.G., Baker, L.R., et al. Microangiopathic haemolytic anaemia and mucin-forming adenocarcinoma. (1970) *J Haematol* 18(2): 183-193.
[PubMed](#) | [Crossref](#) | [Others](#)
- Hayashi, H., Haruyama, H., Emura, Y., et al. Disseminated carcinomatosis of the bone marrow -Study of a type of metastatic cancer and relationship of microangiopathic hemolytic anemia or disseminated intravascular coagulation. (1979) *Jpn J Cancer Clin* 25: 329.
[PubMed](#) | [Crossref](#) | [Others](#)
- Yoshioka, K., Shimizu, H., Yokoo, S., et al. Disseminated carcinomatosis of bone marrow from submucosal carcinoma in adenoma of the rectum. (1992) *Intern Med* 31(8): 1056-1059.
[PubMed](#) | [Crossref](#) | [Others](#)
- Huang, W.T., Chang, K.C., Shan, Y.S., et al. Successful initial treatment with weekly 24-hour infusion of 5-fluorouracil and leucovorin in a rectal cancer patient with acute disseminated intravascular coagulation. (2005) *Hepatogastroenterology* 52(65): 1436-1439.
[PubMed](#) | [Crossref](#) | [Others](#)
- Misawa, R., Kobayashi, M., Ito, M., et al. Primary Colonic Signet Ring Cell Carcinoma Presenting Carcinocythemia: An Autopsy Case. (2008) *Case Rep Gastroenterol* 2(3): 301-307.
[PubMed](#) | [Crossref](#) | [Others](#)
- Naito, M., Yoshida, Y., Aisu, N., et al. A Report of Disseminated Carcinomatosis of the Bone Marrow Originating from Transverse Colon Cancer Successfully Treated with Chemotherapy Using XELOX plus Bevacizumab. (2014) *Case Rep Oncol* 7(2): 426–434.
[PubMed](#) | [Crossref](#) | [Others](#)
- Nakashima, Y., Takeishi, K., Guntani, A., et al. Rectal Cancer With Disseminated Carcinomatosis of the Bone Marrow: Report of a Case. (2014) *Int Surg* 99(5): 518–522.
[PubMed](#) | [Crossref](#) | [Others](#)
- van Bunderen, C.C., de Weger, V.A., Griffioen-Keijzer, A. Disseminated intravascular coagulation as clinical manifestation of colorectal cancer: a case report and review of the literature. (2014) *Neth J Med* 72(4):186-189.
[PubMed](#) | [Crossref](#) | [Others](#)
- Lim, D.H., Lee, S.I., Park, K.W. Bone marrow metastasis of colon cancer as the first site of recurrence: A case report. (2014) *Oncol Lett* 8(6): 2672-2674.
[PubMed](#) | [Crossref](#) | [Others](#)
- Hanamura, F., Shibata, Y., Shirakawa, T., et al. Favorable control of advanced colon adenocarcinoma with severe bone marrow metastasis: A case report. (2016) *Mol Clin Oncol* 5(5): 579-582.
[PubMed](#) | [Crossref](#) | [Others](#)
- Takeyama, H., Sakiyama, T., Wakasa, T., et al. Disseminated carcinomatosis of the bone marrow with disseminated intravascular coagulation as the first symptom of recurrent rectal cancer successfully treated with chemotherapy: A case report and review of the literature. (2017) *Oncol Lett* 13(6): 4290-4294.
[PubMed](#) | [Crossref](#) | [Others](#)
- Nakamura, S., Fukui, T., Suzuki, S., et al. Long-term survival after a favorable response to anti-EGFR antibody plus chemotherapy to treat bone marrow metastasis: a case report of KRAS-wildtype rectal cancer. (2017) *Onco Targets Ther* 10: 1143-1147.
[PubMed](#) | [Crossref](#) | [Others](#)
- Suenaga, M., Mizunuma, N., Matsusaka, S., et al. Phase II study of reintroduction of oxaliplatin for advanced colorectal cancer in patients previously treated with oxaliplatin and irinotecan: RE-OPEN study. (2015) *Drug Des Devel Ther* 9: 3099-3108.
[PubMed](#) | [Crossref](#) | [Others](#)
- Santini, D., Vincenzi, B., Addeo, R., et al. Cetuximab rechallenge in metastatic colorectal cancer patients: how to come away from acquired resistance? (2012) *Ann Oncol* 23(9): 2313-2318.
[PubMed](#) | [Crossref](#) | [Others](#)
- Liu, X., George, G.C., Tsimberidou, A.M., et al. Retreatment with anti-EGFR based therapies in metastatic colorec-

tal cancer: impact of intervening time interval and prior anti-EGFR response. (2015) BMC Cancer 15: 713.

[Pubmed](#) | [Crossref](#) | [Others](#)

21. Shitara, K., Yamanaka, T., Denda, T., et al. REVERCE: A Randomized Phase II Study of Regorafenib Followed by Cetuximab versus the Reverse Sequence for Previously Treated Metastatic Colorectal Cancer Patients. (2018) Ann Oncol 30(2): 259-265.

[Pubmed](#) | [Crossref](#) | [Others](#)

22. Napolitano, S., Martini, G., Rinaldi, B., et al. Primary and Acquired Resistance of Colorectal Cancer to Anti-EGFR Monoclonal Antibody Can Be Overcome by Combined Treatment of Regorafenib with Cetuximab. (2015) Clin Cancer Res 21: 2975-2983.

[Pubmed](#) | [Crossref](#) | [Others](#)

Submit your manuscript to Ommega Publishers and we will help you at every step:

- We accept pre-submission inquiries
- Our selector tool helps you to find the most relevant journal
- We provide round the clock customer support
- Convenient online submission
- Thorough peer review
- Inclusion in all major indexing services
- Maximum visibility for your research

Submit your manuscript at



<https://www.ommegaonline.org/submit-manuscript>