

Comparative between AgNO_3 and KMnO_4 as an Alternate Method of Castration in Lwy Boar

Vanlalmangaihsanga, L.*, Hmar, J. Mohanrao

Department of Veterinary Physiology and Biochemistry, College of Veterinary Sciences & Animal Husbandry, Central Agricultural University, Selesih, Aizawl, Mizoram, India

*Corresponding author: Vanlalmangaihsanga, L., Department of Veterinary Physiology and Biochemistry, College of Veterinary Sciences & Animal Husbandry, Central Agricultural University, Selesih, Aizawl, Mizoram, India, Email: hmangaihatochhong@gmail.com

Abstract

The study aims to determine the efficiency of castration between two different chemicals for castration. The study was carried out in 16 Large White Yorkshire male pigs of 2-3 months and reared till slaughter age. Intratesticular injection of chemical was done when the pig reached the age of 2-3 months for inducing castration in the pig. The animals were divided into two groups consisting of 8 animals in each group, in which in Treatment-1 or T_1 the pigs were castrated chemically using 5% AgNO_3 and for the other group Treatment-2 or T_2 were castrated using KMnO_4 . Statistical analysis revealed that there was no significant ($P>0.05$) difference between the two groups in testicular measurement and the testosterone concentration. But, numerical observation for both of the findings reveals that there was a different between the two treatment groups with lower testicular measurement and testosterone concentration in T_2 group. Histopathologically the testes in T_2 group revealed lesser number of sertoli cells in the testicular tissue and most of the seminiferous tubules were devoid of spermatozoa. From the present finding it may be concluded that castration using KMnO_4 may be the best option for castration of the pigs.

Introduction

Livestock plays an important role for increasing the production of animal origin food like milk, meat and eggs as well as Socio Economic Development of the state. Pork is highly accepted meat in India and abroad. Pork of castrated pig is also preferred to un-castrated one due to the presence of boar taint in the meat. Castration was done mainly when the pigs reached the age of 2-3 months of age^[1]. Breeding boars were also castrated under general anaesthesia after they had become unproductive castrations were performed to decrease the boar taint which is an unpleasant odour which is pronounced upon heating of pork, mainly entire males. The traditional surgical method of castration in pig is highly technical, costly and difficult to adopt by common pig farmer^[2-4]. In addition, the physiological reactions and behaviours of castrated pigs are also modified^[5]. Thus, this experiment was planned to evolve a suitable technology of chemical castration in pigs for reducing the boar taint and also to prevent excessive stress to the animals.

Materials and Method

The study was carried out at Instructional Livestock Farm Complex College of Veterinary Sciences & Animal Husbandry, Central Agricultural University, C.A.U, Selesih, Aizawl, Mizoram, India. A total of 16 24 Large White Yorkshire (LWY) of male

pigs of 2-3 months of age were divided into 2 groups of 8 animals each. In Treatment 1 (T_1), chemical method of castration was conducted by injecting 2 ml of 5% Silver Nitrate Solution intratesticularly as per Kang *et al.* (1993)^[6] and in Treatment 2 (T_2) chemical method of castration was conducted by injecting 2 ml of 0.25 g potassium permanganate + 17 ml glacial acetic acid + 83 ml distilled water intratesticularly as per Giri *et al.* (2002)^[7]. Administration of chemicals was done by sharp needle and syringe pushed through epididymis into the body of testis to discharge the fluid from one end to the other in a withdrawing fashion. Animals of both groups were maintained on uniform feed and managerial condition up to 180th day of castration. Testicular length, breadth and depth of pigs were recorded at monthly intervals. Blood from the pigs were taken at monthly interval and serums were separated for testing the testosterone

Received date: January 20, 2019

Accepted date: February 06, 2020

Published date: February 10, 2020

Citation: Vanlalmangaihsanga, L., et al. Comparative between AgNO_3 and KMnO_4 as an Alternate Method of Castration in Lwy Boar. (2020) J Vet Sci Animal Welf 4(1): 10-13.

Copy Rights: © 2020 Vanlalmangaihsanga, L. This is an Open access article distributed under the terms of Creative Commons Attribution 4.0 International License.

concentration. Histopathological study of the testis recovered from chemically castrated group was conducted to find out the changes in the testis. Finally statistical analysis was done using SPSS package 20.0

Results and Discussion

Testicular measurement (mm)

The mean \pm SE of testicular measurement (mm) of LWY male pigs at 2 month of age are presented in Table 1. There were no significant differences between the treatment group in testicular measurement, the mean measurement of the testis for the length, breadth and depth under the treatment T₁ and T₂ were 38.00 \pm 0.58 & 38.93 \pm 0.37; 15.97 \pm 0.49 & 16.67 \pm 0.17 and 14.50 \pm 0.36 & 14.6 \pm 0.87 mm respectively. In T₁ it was found that there was an increasing trend in the length, breadth and depth of the testicles till the end of the rearing period i.e. 180 days, but the final measurement in the present study was found to be lesser than the finding of Singh *et al.* (2018)^[7] who had done the gross morphological study of the testes in LWY intact boars. The increase in the size of the testes from 4th months of age in T₁ may be due to regeneration of the testicular tissue in the later stage of the rearing period. The increase in the size of the testes may be the reason for increase in the concentration of the testosterone hormone, as the size of testes is correlated with the amount of testosterone production, which was in support by the findings of Bekaert *et al.* (2012)^[8] and Bernau *et al.* (2018)^[9,10]. Whereas, in T₂ that there were decreased in the size of the testes from 4 months to 5 months of age and from 6 months the testicle was complete atrophied hence, measurement was not possible. This finding is similar to the finding of Giri *et al.* (2002)^[7] and Kang *et al.* (1993)^[6] who had observed that the testicles had completely atrophied in chemical castration and later act as a rudimentary organ in pig later stage of life.

Table 1: Mean Testicular Measurement between the Different Treatments at age (mm)

Age (Months)	Measurement (mm)	Treatment group		t value	p Value
		T1	T2		
2	Length	38.00 \pm 0.58	38.93 \pm 0.37	1.06 ^{NS}	0.10
	Breadth	15.97 \pm 0.49	16.67 \pm 0.17	0.95 ^{NS}	0.52
	Depth	14.50 \pm 0.36	14.6 \pm 0.87	0.04 ^{NS}	0.66
3	Length	39.67 \pm 0.33	40.83 \pm 0.44	2.11 ^{NS}	0.10
	Breadth	17.33 \pm 0.33	18.57 \pm 0.35	2.57 ^{NS}	0.62
	Depth	16.00 \pm 0.58	16.27 \pm 1.11	0.19 ^{NS}	0.56
4	Length	55.00 \pm 5.00	31.47 \pm 10.77	2.00 ^{NS}	0.12
	Breadth	56.63 \pm 1.26	14.67 \pm 6.12	1.68 ^{NS}	0.17
	Depth	19.13 \pm 0.38	11.40 \pm 3.80	2.02 ^{NS}	0.11
5	Length	72.67 \pm 3.93	27.10 \pm 16.95	2.43 ^{NS}	0.13
	Breadth	28.97 \pm 1.93	12.50 \pm 9.65	1.78 ^{NS}	0.21
	Depth	21.80 \pm 0.46	8.97 \pm 6.27	2.03 ^{NS}	0.11

(* Significant (P \leq 0.05), (** Significant (P \leq 0.01) and NS Non-significant

Note: Means bearing at least one common superscript in each row do not differ significantly.

Testosterone Concentration (pg/ml)

The mean testosterone concentrations (pg/ml) for T₁ and T₂ at 6 months age were 2148.17 \pm 604.06 and 1879.33 \pm 252.70 pg/ml as shown in Table 2. Statistical analysis shows a non-significant difference between the groups, which might be due to the high standard deviation which may result in non applicable to statistical treatment. The concentration of testosterone level in T₁ and T₂ group though reduced at 3 months was found to increase subsequently. The present finding was in contrast with the findings of Fahim (1994)^[11] (7) who had reported that testosterone concentration decreases at 22 weeks of age when animals was injected with 100 mg of zinc arginine intratesticularly in pigs. Same findings was also reported in other species of animals by Vanderstichel *et al.* (2014)^[12] in dogs by using different chemicals; Al-Asadi & Al-Kadi (2012)^[13] (1) in bucks after chemical castration; Canpolat *et al.* (2006)^[14] and Cohen *et al.* (1991)^[15-18] in bulls. The variations in the findings may be due to partial destruction of the testes, or especially due to the partial immunity of the interstitial cells being destroyed. It might also be due to the fact that there was a regeneration of the testicular tissue from the 5th months of age, which led to higher concentration of the hormones testosterone.

Table 2: Mean testosterone concentration between the different treatments at different age. (Pg/ml)

Age (Months)	Treatment group			F value	P value
	C	T1	T2		
2	1574.13 \pm 884.62	1006.07 \pm 220.12	1145.10 \pm 126.55	0.16 ^{NS}	0.85
3	1293.5 \pm 420.49	886.07 \pm 272.93	934.13 \pm 63.48	0.49 ^{NS}	0.63
4	926.83 \pm 135.53	952.73 \pm 207.87	867.47 \pm 4.04	0.56 ^{NS}	0.60
5	860.17 \pm 102.481	1119.40 \pm 117.01	997.50 \pm 31.75	2.00 ^{NS}	0.22
6	800.80 \pm 436.69	2148.17 \pm 604.06	1879.33 \pm 252.70	2.79 ^{NS}	0.14

(* Significant (P \leq 0.05), (** Significant (P \leq 0.01) and NS Non-significant

Note: Means bearing at least one common superscript in each row do not differ significantly.

Histopathology

The present study reveals that in T₁ treatment group there was a remarkable increased population of interstitial cells, seminiferous tubules containing a tuft of developing spermatozoa with tails and sertoli cells in the tubules. But no mature spermatozoa could be seen in the centre of the seminiferous tubules.

While in T₂ the testicular tissue showed a remarkable increased in the population of interstitial cells but the tubules were vacuolated with no spermatozoa. The findings were in accordance with the report of Giri *et al.* (2002)^[7].

The histopathological study of the testes of T₂ group reveals that due to lesser number of sertoli cells in the testicular tissue and most of the seminiferous tubules were devoid of spermatozoa. The interstitial cells showed hypertrophy giving an adenoid appearance (Figure.1) with necrobiotic changes in

few cells. The present findings in T_1 and T_2 may be concluded that due to irritation caused by chemical castration, the seminiferous tubules were devoid of spermatozoa and there was disappearance of germinal cells due to its delicate structure and high sensitivity to chemicals. However, the interstitial cells being less sensitive to such chemicals got better nourished in post inflammatory period and become hypertrophied with adenomatous appearance, which might be due to continued secretion of androgen (Giri *et al.*, 2002)^[7].

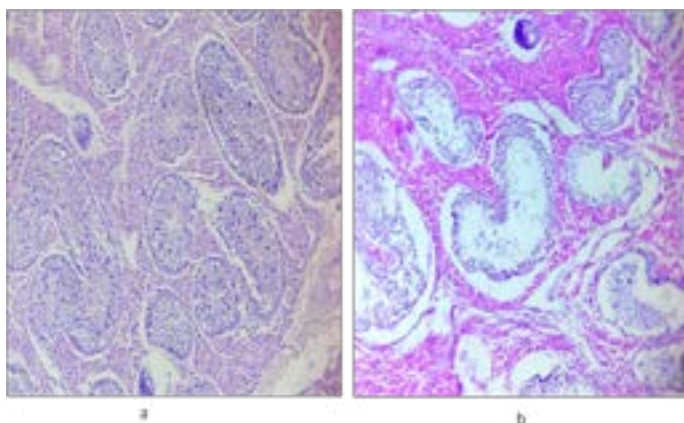


Figure 1: (a) Cross section of testicle in pigs under chemical castration with $AgNO_3$ solution (T_1). (b) Cross section of testicle of pig under chemical castration with $KMnO_4$ solution (T_2). (Testis H & E 400X)

Conclusion

From the present study statistical analysis reveals no significant difference between the treatment groups, but numerical values reveals that in T_2 groups there were lower testicular measurement and testosterone concentration. Further, a T_2 group shows a significant change in the histopathological morphology. It may thus be concluded that chemical castration by $KMnO_4$ may be a better method in castration of the pigs. But, further research may be carried out on chemical castration for longer rearing period to ascertain the present finding.

References

1. Bonneau, M., Meadus, W.J., Squires, E.J. Effects of exogenous porcine somatotropin on performance, testicular steroid production and fat levels of boar-taint-related compounds in young boars. (1992) *Canadian J Anim Sci* 72(3): 537-545.
[Pubmed](#) | [Crossref](#) | [Others](#)
2. Hay, M., Vulin, A., Genin, S., *et al.* Assessment of pain induced by castration in piglets: behavioral and physiological responses over the subsequent 5 days. (2003) *Appl Anim Behav Sci* 82(3): 201-218.
[Pubmed](#) | [Crossref](#) | [Others](#)
3. Jaros, P., Burgi, E., Stark, K.B.C., *et al.* Effect of active immunization against GnRH on androstenone concentration, growth performance and carcass quality in intact male pigs. (2005) *Livest Sci* 92(1): 31-38.
[Pubmed](#) | [Crossref](#) | [Others](#)
4. Prunier, A., Bonneau, M., von Borell, E.H., *et al.* A review of the welfare consequences of surgical castration in piglets and the evaluation of non-surgical methods. (2006) *Animal Welfare* 15(3): 277-289.
[Pubmed](#) | [Crossref](#) | [Others](#)
5. Marx, G., Horn, T., Thielebein, J., *et al.* Analysis of pain-related vocalization in young pigs. (2003) *J Sound and Vibration* 266(3): 687-698.
[Pubmed](#) | [Crossref](#) | [Others](#)
6. Kang, Y.S., Park, C.S. and Chung, H.S. Chemical castration by intracellular injection of silver nitrate solution in pigs. (1993) *Korean J Anim Sci* 35: 463-469.
[Pubmed](#) | [Crossref](#) | [Others](#)
7. Giri, S.C., Yadav, B.P.S. and Pand, S.K. Chemical castration in pigs. (2002) *Indian J Anim Sci* 72(6): 451-453.
[Pubmed](#) | [Crossref](#) | [Others](#)
8. Singh, T.S., Kalita, P.C., Kalita, A., *et al.* Comparative Gross Anatomical Studies on the Testes of Zovawk (Mizo Local Pig) and Large White Yorkshire Pig. (2018) *Inter J of Livestock Research* 9(2): 91-94.
[Pubmed](#) | [Crossref](#) | [Others](#)
9. Bekaert, K.M., Aluwé, M., Millet, S., *et al.* (2012). Predicting the likelihood of developing boar taint: early physical indicators in entire male pigs. *Meat science* 92(4): 382-385.
[Pubmed](#) | [Crossref](#) | [Others](#)
10. Bernau, M., Schwanitz, S., Kremer-Rücker, P.V., *et al.* Size matters: Boar taint in relationship with body composition and testis volume measured by magnetic resonance imaging. (2018) *Livestock Science* 213: 7-13.
[Pubmed](#) | [Crossref](#) | [Others](#)
11. Fahim, M.S. Chemical castration. United States Patent 5372822, Application No. 206469. (1994) IOP United States Patent and Trademark Office
[Pubmed](#) | [Crossref](#) | [Others](#)
12. Vanderstichel, R., Forzan, M.J., Perez, G.E., *et al.* Changes in blood testosterone concentrations after surgical and chemical sterilization of male free-roaming dogs in southern Chile. (2015) *Theriogenology* 83(6): 1021-1027.
[Pubmed](#) | [Crossref](#) | [Others](#)
13. Al-Asadi, R.N., Al-Kadi, K.K. Non-surgical castration in bucks a comparative study between chemical castration and external ligation of the spermatic cord. (2012) *AL-Qadisiyah Journal of Veterinary Medicine Sciences* 11(1): 92-102.
[Pubmed](#) | [Crossref](#) | [Others](#)
14. Canpolat, I., Gur, S., Gunay, C., *et al.* An evaluation of the outcome of bull castration by intra-testicular injection of ethanol and calcium chloride. (2006) *Revue de médecine vétérinaire* 157(8/9): 420.
[Pubmed](#) | [Crossref](#) | [Others](#)
15. McGlone, J.J., Hellman, J.M. Local and general anesthetic effects on behaviour and performance of two and seven-week old castrated and uncastrated piglets. (1988) *J Anim Sci* 66(12): 3049-3058.
[Pubmed](#) | [Crossref](#) | [Others](#)
16. McGlone, J.J., Nicholson, R.I., Hellman, J.M. and Herzog, D.N. (1993). The development of pain in young pigs associated with castration and attempts to prevent castration-induced behavioural changes. *J Anim Sci* 71(6): 1441-1446.
[Pubmed](#) | [Crossref](#) | [Others](#)

[Pubmed](#) | [Crossref](#) | [Others](#)

17. Patterson, R.L.S. 5 α -androst-16-ene-3-one:—Compound responsible for taint in boar fat. (1968) *Journal of the Science of Food and Agriculture* 19(1): 31-38.

[Pubmed](#) | [Crossref](#) | [Others](#)

18. Cohen, R.D.H., King, B.D., Hunter, P.S.W., *et al.* Efficacy of chemical castration and effects of age at castration and implant regime on growth rate, testicular measurements and testosterone levels of beef calves. (1991) *Canadian J Anim Sci* 71(1): 1-11.

[Pubmed](#) | [Crossref](#) | [Others](#)

Submit your manuscript to Ommega Publishers and we will help you at every step:

- We accept pre-submission inquiries
- Our selector tool helps you to find the most relevant journal
- We provide round the clock customer support
- Convenient online submission
- Thorough peer review
- Inclusion in all major indexing services
- Maximum visibility for your research

Submit your manuscript at



<https://www.ommegaonline.org/submit-manuscript>