



Case Report

## Treatment of Eyeliner Tattoo Using an 810 nm Diode Laser: A Case Study of Safety and Efficacy

**Randal Tanh Hoang Pham\***

Aesthetic and Refractive Surgery Medical Center & Advanced Surgery Medical Center, San Jose, CA, USA

**Corresponding author:** Randal Tanh Hoang Pham, MD, Aesthetic and Refractive Surgery Medical Center & Advanced Surgery Medical Center, 989 Story Road, Suite 8063, San Jose, CA 95122, USA. E-mail: [randalpham@lasernews.com](mailto:randalpham@lasernews.com)

### Abstract

An 80 year-old Asian female patient with misplaced eyeliner tattoo was treated with an 810 nm diode laser. A review of the literature examining the use of eyeliner removal lasers with respect to safety and efficacy around the eye was conducted. The successful use of an 810 nm diode laser in this case established the safety and efficacy for utilizing an 810 nm diode laser in the periorbital area for eyeliner tattoo removal.

**Received Date: June 10, 2015**

**Accepted Date: July 31, 2015**

**Published Date: August 4, 2015**

**Keywords:** Laser; Eye; Eyelid; Eyeliner; Tattoos; Eyeliner tattoo removal

**Citation:** Pham, R. T. H. Treatment of Eyeliner Tattoo Using an 810 nm Diode Laser: A Case Study of Safety and Efficacy. (2015) *J Invest Dermatol, Venereol Cosmetol* 1(1): 17- 19.

### Introduction

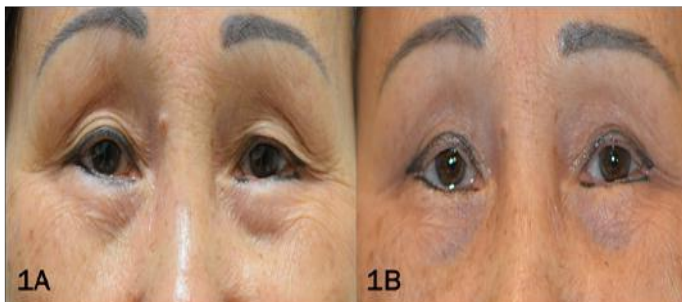
The practice of eyeliner tattooing has gained more popularity in recent years. Both the number of procedures performed and the number of complications associated with eyeliner tattooing have increased. Misplaced eyeliner tattoo was among the most common complications noted with eyeliner tattooing procedures<sup>[1]</sup>. With the recent development of new lasers for removal of tattoos such as the picosecond laser, treatments of eyeliner tattoo using these lasers will become more common. This study is the only study in the literature addressing the safety and efficacy of the use of lasers for eyeliner tattoo removal in the periorbital region.

### Methods

An 80 year-old Asian female patient with misplaced dark blue eyeliner tattoo of the left lower lid [Figure 1A] underwent laser removal of eyeliner tattoo. The procedure involved seating the patient at the Haag Streit model 900 BM slit lamp (Haag Streit USA, Mason, Ohio, USA), applying a drop of 0.5% of proparacaine hydrochloride ophthalmic solution (Akorn Pharmaceuticals, Lake Forest, Illinois, USA) into both eyes, placing Cox III metal eye shields (Oculo-Plastik, Inc, Montreal, Quebec, Canada) on both eyes. Topical eutectic mixture of lidocaine-prilocaine anesthesia (E.M.L.A.) cream (AstraZeneca, London, UK) was applied to the left lower lid over the area of misplaced eyeliner tattoo near the lateral canthus. The 4mm laser tip of an 810 nm diode (Dioderm) laser (Cynosure, Chelmsford, MA, USA) was placed in direct contact with the tattooed area of the left lower lid [Figure 1A]. The 810 nm diode laser was fired with the pulse duration (pulse width) of 50 milliseconds and an energy density of 15 J/cm<sup>2</sup>. A total of 3 passes was performed. Aquaphor ointment (Beiersdorf AG, Hamburg, Germany) was applied to the treated area immediately after treatment. The patient was asked to report any flashing light, pain, or other abnormalities that occurred during or immediately after the laser treatment, and throughout the 24 hr post-operative period. Complete eye examinations including visual acuities, slit lamp examinations and fundus examinations were performed before treatment, 24 hrs after treatment, 1 week after treatment, 2 weeks after treatment, 1 month after treatment, 3 months after treatment and 6 months after treatment.

**Copy rights:** ©2015 Pham, R. T. H. This is an Open access article distributed under the terms of Creative Commons Attribution 4.0 International License.

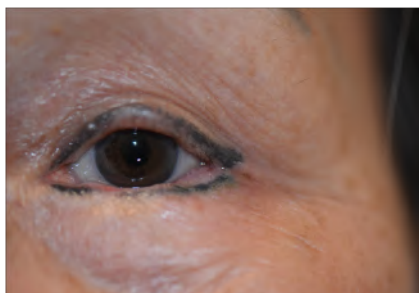
**DOI:** 10.15436/2381-0858.15.004



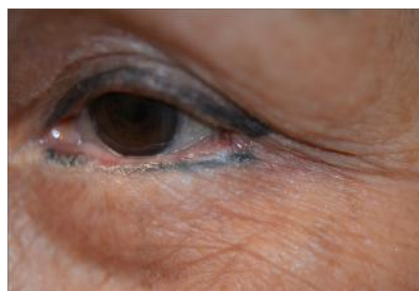**Figures 1A and 1B:** 1A) 80 year-old Asian female with misplaced eyeliner tattoo on the left lower eyelid near the lateral canthus before laser treatment. 1B) Same patient 2 weeks after laser treatment.

## Results

Significant lightening of the eyeliner tattoo was observed after laser treatment [Figures 1B, 2 and 3]. The patient reported no abnormal symptom during laser treatment, immediately after treatment and during the 24 hr post-operative period and was extremely satisfied with the aesthetic result. Ocular examination revealed no abnormality at 1 day, 1 week, 2 weeks, 1 month, 3 months or 6 months after laser treatment. No scarring, allergic reaction, hyperpigmentation or hypopigmentation was noted following the laser treatment.



**Figure 2:** Close up photograph of left eye of same patient 1 day after laser treatment.



**Figure 3:** Close up photograph of left eye of same patient 2 weeks after laser treatment.

## Discussion

This report is the first study to use an 810 nm diode laser to treat eyeliner tattoo. A previous study used an 810 nm diode laser to treat trichiasis and found the laser to be effective at an energy level of 70 J/cm<sup>2</sup>, well below the energy level of 80 J/cm<sup>2</sup> established by a previous safety study<sup>[2,3]</sup>. The energy used in the present study was 15 J/cm<sup>2</sup>. The low energy was selected

because of the abundance of dark pigments in the eyeliner tattoo as compared to pigmented hair follicles. Higher energy levels may produce severe thermal damage that results in scarring of the eyelid and possible damage to meibomian glands, which were shown to be affected by eyeliner tattoos<sup>[4]</sup>.

In 1964, Dr. Leon Goldman developed the first laser for tattoo removal, a normal mode ruby laser<sup>[5]</sup>. The development of the Q-switched ruby, the Q-switched Nd: Yag and the Q-switched alexandrite lasers popularized the use of lasers for tattoo removal because of lesser side effects such as scarring, hyperpigmentation and hypopigmentation<sup>[5]</sup>. The shock waves produced by the Q-switched laser break down cells that contain tattoo pigments and cause these pigments to be broken down and then reabsorbed and removed by macrophages<sup>[6]</sup>. The argon laser, on the other hand, inflicts thermal injury to the pigment containing cells causing them to release pigments into the surrounding tissue. These pigments in turn are absorbed by fibroblasts, macrophages and neutrophils and removed from the skin<sup>[5]</sup>. Because of its longer wavelength (810 nm) the diode laser penetrates eyelid tissue deeper than the argon laser (488 nm to 514 nm), thus causing absorption of thermal energy at a greater depth<sup>[3]</sup>. However, unlike the argon laser which is a continuous wave emitting laser, the diode laser has a short pulse width of 50 milliseconds and a longer wavelength that allows greater and deeper light absorption by pigments without heating the surrounding tissue<sup>[3]</sup>. The short pulse width minimizes thermal damage to the surrounding tissue, thus preventing the occurrence of post-inflammatory hyperpigmentation, a common complication observed in Asians after either ablative or non-ablative laser treatments<sup>[7]</sup>. This concept of achieving extremely short pulse width to minimize thermal damage to the surrounding tissue provides the framework for the development of picosecond laser technology.

In 1986, Dr. David Wilkes reported the complications caused by eyeliner tattoos and noted a complication rate of 12%<sup>[8]</sup>. Complications included infections, allergic reactions and a possible association with eyelid tumors. These findings, however, did not stop the practice of eyeliner tattooing which is currently performed by a large number of aestheticians. Given the large number of eyeliner tattoo procedures performed at this time, it is suspected that a large number of eyeliner tattoo removal was also performed. In 1992, Watts et al. reported the use of Q-switched Nd:Yag laser for removal eyeliner tattoo<sup>[9]</sup>. However, there has been no study conducted to date that examined the safety of Q-switched ruby, Nd:YAG, and alexandrite lasers when used on the eyelid. The study conducted by Pham et al. was the only ERG study assessing the safety of the use of laser in the periorbital region<sup>[2]</sup>. This report is the only report to date on the efficacy of a laser that has been shown to be safe for usage near the eye.

## Conclusion

The 810 nm diode laser is safe and effective in removing eyeliner tattoos if safety measures are observed and energy levels are appropriately chosen.

## Financial Disclosure

The author has no financial interest in any of the products mentioned in this manuscript.

### Acknowledgments

The author wishes to thank Beverley Murray, PhD for her assistance in the preparation of this manuscript.

### Presentation

This study was presented in part at the Skin Aging, Facial Plastic and Aesthetic Surgery (SAFPAS) 15<sup>th</sup> Annual Meeting of the California Society of Facial Plastic Surgery in Lake Tahoe, California, USA, March 1, 2015.

### References

1. Bernstein, E. F. Laser treatment of tattoos. (2006) *Clin Dermatol* 24(1): 43-55.
2. Pham, R. T., Biesman, B. S., Silkiss, R. Z. Treatment of trichiasis using an 810 nm diode laser: an efficacy study. (2006) *Ophthal Plast Reconstr Surg* 22(6): 445-447.
3. Pham, R.T., Biesman, B. S., Marmor, M. F., et al. Retinal evaluation after 810 nm Dioderm laser removal of eyelashes. (2002) *Dermatol Surg* 28(9): 836-840.
4. Lee, Y. B., Kim, J. J., Hyon, J. Y., et al. Eyelid tattooing induces meibomian gland loss and tear film instability. (2015) *Cornea* 34(7): 750-755.
5. Kuperman-Beade, M., Levine, V. J., Ashinoff, R. Laser removal of tattoos. (2001) *Am J Clin Dermatol* 2(1): 21-25.
6. Reid, W. H., Miller, I. D., Murphy, M. J., et al. Q-switched ruby laser treatment of tattoos; a 9-year experience. (1990) *Br J Plast Surg* 43(6): 663-669.
7. Pham, R. T., Mattoch, I., Baker, S. S. Periorbital post-inflammatory hyperpigmentation after fractionated CO<sub>2</sub> laser resurfacing in Asians. (2015) *Modern Plastic Surgery* 5: 9-13.
8. Wilkes, T. D. The complications of dermal tattooing. (1986) *Ophthal Plast Reconstr Surg* 2(1): 1-6.
9. Watts, M. T., Downes, R. N., Collin, J. R., et al. The use of Q-switched Nd:Yag laser for removal of permanent eyeliner tattoo. (1992) *Ophthal Plast Reconstr Surg* 8(4): 292-294.