

Challenges and Prospects of Awake Craniotomy in a Resource-Poor Setting

Abiodun I Okunlola¹, Cecilia K Okunlola², Olakunle F Babalola¹, Paul Olowoyo³, Tesleem O Orewole⁴, Abayomi P Aremu⁴, Taophee B Rabi⁵, Olabande O Ajayi¹

¹Department of Surgery, Federal Teaching Hospital Ido-Ekiti/ Afe Babalola University, Ado-Ekiti, Nigeria.

²Department of Clinical Pharmacology, University College Hospital, Ibadan, Nigeria

³Department of Medicine, Federal Teaching Hospital Ido-Ekiti/ Afe Babalola University, Ado-Ekiti, Nigeria.

⁴Department of Anesthesia, Federal Teaching Hospital, Ido-Ekiti, Nigeria

⁵Department of Surgery, LAUTECH Teaching Hospital, Osogbo, Nigeria

*Corresponding author: Dr. Abiodun Idowu Okunlola, Department of Surgery, Federal Teaching Hospital, Ido-Ekiti, Nigeria, Tel: +2348038112012; E-mail: okunlolab@yahoo.com

Abstract

Background: The trend in neurosurgery is towards awake craniotomy in a suitable patient to minimize the risk of anesthesia, allow intraoperative monitoring of the patient's function and reduce operative morbidity. This has not been widely utilized in poor resource settings like our center where both human and material resources are limited.

Aim: The aim of this review is to document the challenges and prospects of awake craniotomy in resource-poor settings.

Methodology: The Federal Teaching Hospital Ido-Ekiti is located in a suburban community in South Western Nigeria with minimally active neurosurgical practice due to limited human and material resources. Two patients with right frontal brain tumor abutting on the motor cortex had awake craniotomy and gross total tumor excision under low dose sedation with propofol and local anesthesia.

Results: Both patients complained of tolerable discomfort during bone work. We achieved a gross total tumor excision in both cases and there was no need to convert to general anesthesia. Both patients were fully awake at the end of their surgery and there was an improvement in their headache and hemiparesis.

Conclusion: Awake craniotomy is commonly practiced in well-established neurosurgical facilities across the globe but it should be considered as an option in resource-poor settings in suitable patients to reduce operative morbidity and pressure on the limited human and material resources.

Keywords: Awake craniotomy; Brain tumor; Sedation; Local anesthesia; Propofol

Introduction

Awake craniotomy is a well-established procedure used during surgery for intracranial masses that involve or abut on eloquent brain regions but this practice is still very limited in our region due to non-availability of both human and material resources^[1,2]. It is defined as craniotomy in an awake patient although the patient does not need to be awake throughout the procedure. Awake craniotomy is growing in popularity among neurosurgeons, to the extent that it has been suggested that it should be used for all brain tumor excisions^[3]. Traditional indications for awake craniotomy with intra-operative mapping and monitoring include preservation of motor and language functions^[1,4]. Awake craniotomy with intra-operative mapping and monitoring has been reported to be associated with better neurological outcome, more extensive tumor resection, and shorter length of hospital stay^[5-7]. The acquisition of electro-cortical mapping tools used for the detection and sparing of eloquent brain regions is not feasible to all centers, most especially those in the developing countries^[8]. Neuroanesthesia in awake craniotomy is important for keeping the patient cooperative during the mapping phase as well as

Received date: June 11, 2019

Accepted date: July 18, 2019

Published date: July 24, 2019

Citation: Okunlola, A.I., et al. Challenges and Prospects of Awake Craniotomy in a Resource-Poor Setting. (2019) Intl J Neuro Brain Dis 6(1): 17-20.

Copy Rights: © 2019 Okunlola, A.I. This is an Open access article distributed under the terms of Creative Commons Attribution 4.0 International License.

for decreasing the physical and psychological stress associated with this procedure^[2,7]. Patients operated using awake craniotomy are not exposed to possible complications associated with general anesthesia and awake craniotomy can be performed as an outpatient procedure^[9]. Experienced neuroanesthetists usually developed a preferred technique but there are no significant differences in outcome of the various anesthetic protocols for awake craniotomy^[6,10-12]. Local anesthesia is the corner stone of any awake craniotomy technique, and this is typically provided by means of a scalp block, which if performed well with agents such as Bupivacaine, Levobupivacaine or Ropivacaine, can provide good and safe analgesia for eight hours or longer^[3,8,11]. Indications for awake craniotomy have only focused on the tumor location without consideration of available resources in different neurosurgical center which is the main factor affecting neurosurgical practice in our region. The aim of this review is to document the challenges, benefits and prospects of awake craniotomy in a resource-poor setting.

Study Location

The Federal Teaching Hospital, Ido-Ekiti is located in a suburban community in South Western Nigeria. Neurosurgery practice has been minimally active in our center due to limited human and material resources. The Centre has the basic cranial set and diathermy machine. There is no rigid head holder, neurophysiological monitor or neuroimaging facility. We have four bedded intensive care unit with only one functioning mechanical ventilator. We do not have access to neuro-anesthetist with experience in awake craniotomy. There is a limited resource for optimal neurosurgery practice in our Centre which necessitated modification of our practice to optimize our limited facilities. We commenced awake craniotomy to facilitate active neurosurgical services.

Patients

Two patients with right frontal brain tumours abutting on the motor cortex were recruited in July 2018 for the commencement of awake craniotomy. The first patient is a fifty-six-year-old man with right frontal meningioma (figure 1) and Karnofsky Performance Score (KPS) 50. The second patient is a sixty-year-old woman with a right frontal metastatic brain tumor (figure 2) and Karnofsky Performance Score (KPS) 30. Both tumours were abutting on the motor cortex. These patients had the awake craniotomy and gross total tumor excision. The details of the surgery and theatre environment were explained to the patients and their relatives. Consent was taken for awake craniotomy and tumor excision. Both patients had scalp hair shaved with electric clippers a day prior to their surgery. Oral anticonvulsants were given with sips of water at 6:00 am on the day of surgery to prevent intra-operative seizures because both patients were on anticonvulsants^[13].

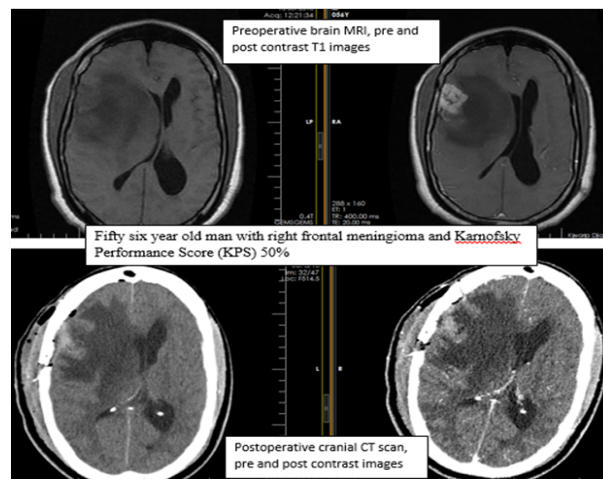


Figure 1: Case one with right frontal meningioma

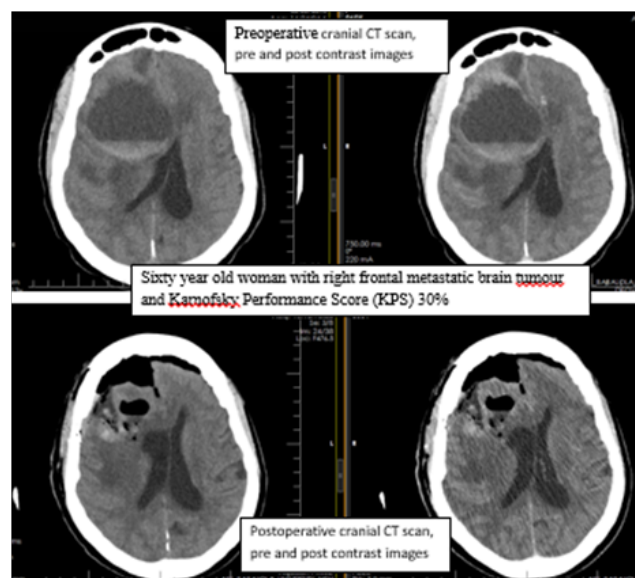


Figure 2: Case two with right frontal metastatic brain tumour

Intraoperative Management

Oxygen was supplemented through a nasal cannula. Urinary catheter and Paul's tube were used for the female and male patients respectively. They were sedated with 5 ml of IV 1% propofol bolus for scalp nerve block. A local anesthetic solution was prepared with 10 ml of 0.5% bupivacaine, 10 ml of 2% xylocaine with adrenaline and 20 ml of sterile water for injection to make 40 ml of local anaesthesia which contains 0.5% xylocaine and 0.125% Bupivacaine.

Ipsilateral supraorbital, supratrochlear, auriculotemporal, zygomaticotemporal, posterior auricular branches of greater auricular nerve, greater and lesser occipital nerves were blocked and additional infiltration of the incision line was achieved with the local anesthetic solution. Sterile surgical drapes were applied to isolate the operation site. Patients were awake during scalp incision until the completion of the craniotomy. The craniotomy was achieved with four Burrholes made with Hudson brace and perforator and connected with Gigli saw. Repeat sedation was done with 3 ml of IV 1% propofol for dural opening. Patients were awake throughout the remaining part of the surgery. The patient was monitored with multiparameter monitor to deter-

mine the SPO₂, Pulse rate, Blood Pressure and the mean arterial blood pressure. The head stabilization was achieved with the assistant surgeon's hand when necessary and handheld brain retractor was used for brain retraction. The patients' function was monitored intraoperatively with verbal communication and examination of the affected hemibody. Anesthetist was available for patient monitoring and prepared for conversion to general anesthesia if indicated. The patients, their spouses and relations were interviewed after the surgery. We used paracetamol as an adjunct analgesic for our perioperative analgesia.

Results

The patients and their relations were all motivated to participate in the commencement of awake craniotomy in our center despite limited facility. Both patients complained of tolerable discomfort during bone work. We achieved gross total tumor excision in both cases. The duration of surgery was about three hours for each. There was no need for conversion to general anesthesia or intraoperative seizures. Both patients were fully awake at the end of their surgery and there was an improvement of their hemiparesis. The patients had their post-operative cranial CT scan within 24 hours post operation at a medical facility which is about 90 minutes' drive from our center. The post-operative cranial CT scan showed gross total tumor excision in both cases. The patients had progressive improvement in their Karnofsky Performance Score (KPS). The fifty-six-year-old man with right frontal meningioma and pre-operative KPS 50 was discharged home on post-operative day 5 with KPS 80 while the sixty-year-old woman with right frontal metastatic brain tumor and pre-operative KPS 30 was discharged home on post-operative day 8 with KPS 70. Both patients have returned to their premorbid activities with KPS 100 at outpatient clinic review five months post operation.

Discussion

Awake craniotomy is one of the new trends in neurosurgery designed to minimize risk of anesthesia, allow intraoperative monitoring of the patient's function and reduce operative morbidity^[1,14]. The trend may be limited in poor resource settings as our center where both human and material resources are limited. We tried to experiment awake craniotomy with readiness to convert to general anesthesia when needed. We selected two patients who presented with right frontal brain tumor adjacent to the motor cortex. The success of awake craniotomy is related to good patient selection along with experienced neuroanesthetist and intra-operative neurophysiological monitors which are not available in our centre^[6].

Adequate preoperative evaluation of the neuroimaging which includes the assessment of the tumour margin and resectability without significant risk of neurological deficit and optimal planning with the patients on what is expected intra-operatively could have been responsible for successful awake craniotomy in our centre^[7,15]. The goal of awake craniotomy in reducing operative morbidity and anesthetic risk with optimal tumor resection was achieved in our initial successful awake craniotomies. There was no need for postoperative intensive care unit admission and both patients were able to travel for post-operative cranial

CT scan within 24 hours of their surgery^[1]. The patients complained of tolerable discomfort during bone work but they were not suggesting further sedation^[11]. The patients did not express any regret participating in the awake craniotomy technique^[16]. They reported they would undergo the awake craniotomy again if necessitated in the future and will recommend it for others patients^[17]. Awake craniotomy is evolving as a procedure of choice in well-established neurosurgical facilities across the globe and this can also be a viable trend in our region^[14].

Non-availability of experienced anesthetists and appropriate equipment has been a challenge in resource-poor settings but modification of the procedure based on the available resources will make it a viable option to reduce operative morbidity and reduce pressure on the limited medical and surgical facilities. There is no consensus regarding the ideal anesthetic technique for awake craniotomy, but the common target for all techniques is to facilitate maximum possible tumor resection with preservation of normal brain function^[8]. Our minimal patient sedation and judicious use of local anesthetic solution for scalp nerves block provided us with the means of achieving the desired end result without compromising patients' functions^[14]. We used low dose propofol to achieve light sedation and avoid respiratory depression^[11]. Unilateral scalp block was achieved with 40 ml of the local anesthetic solution prepared with 10 ml of 0.5% plain bupivacaine, 10 ml of 2% xylocaine with adrenaline and 20 ml of sterile water for injection to make the solution which contains 0.5% xylocaine and 0.125% bupivacaine to reduce the risk of drug toxicity^[12,18,19]. This low dose protocol allowed craniotomy using scalp block and sedation with unsupported airway^[8]. Non availability of rigid head holder made us avoid the use of rigid brain retractor to avoid traction injury to the brain in case the patient moved the head against the rigid brain retractor. We use handheld brain retractor which could be easily relaxed in case the patient moved.

Electrophysiological monitoring is central to the neurological outcome of awake craniotomy and tumour excision in eloquent brain regions but this facility is not available in our hospital at the moment^[6]. The use of intraoperative neurological examination was used to reduce the risk of neurological damage. There is significant limitation of the neurological examination alone and this should be used as an adjunct to brain mapping to prevent permanent neurological deficit^[9].

The short post-operative hospital stay and ability to nurse the patients on a general ward reduced the cost of care for the patients and made the procedure more acceptable to the patients and their relatives but the time of discharge should be tailored based on the patient pre and post-operative clinical and radiological factors^[20,21]. The practice of Awake Craniotomy has widened to include routine procedures that do not involve awake functional cortical mapping or electrophysiological recordings like stereotactic brain biopsy, ventriculostomy, the evacuation of intracranial hematomas and drainage of intra-cerebral abscess^[9,22]. Awake craniotomy is increasing as a viable option for supratentorial lesions. This review renew hope that with acquisition of basic brain mapping equipment, awake craniotomy, though being practiced in the sophisticated neurological surgery centres, will be a viable option in the resource-poor settings.

Conclusion

Awake craniotomy is commonly practiced in well-established neurosurgical facilities across the globe but it should be considered as an option in resource-poor settings in suitable patients to reduce operative morbidity and pressure on the limited human and material resources without compromising outcome.

Key messages: The key message is to document the various challenges of optimal neurosurgical practice, including awake craniotomy, in resource poor setting and to proffer possible solutions. This includes the benefits of modifying awake craniotomy to suit the available facilities.

Source of support: No external support was received for this work

Conflicts of interests: The authors declared no conflict of interests.

Acknowledgements: We acknowledge Dr. Kunle Ajayi, the Chief Medical Director and Dr. Idowu Adebara, the Chairman, Medical Advisory Committee, Federal Teaching Hospital, Ido-Ekiti, Nigeria for their support for the actualization of this project.

References

1. Kobayakov, G.L., Lubnin, A.Y.U., Kulikov, A.S., et al. "Awake Craniotomy." (2016) Problems of neurosurgery named after N.N. Burdenko 1: 88–96.
[PubMed](#) | [CrossRef](#) | [Others](#)
2. Nazaruddin, W.M., Hassan, W., Lukman, M.F., et al. "Awake Craniotomy : A Case Series of Anaesthetic Management Using a Combination of Scalp Block , Dexmedetomidine and Remifentanyl in Hospital Universiti Sains Malaysia. (2013) Med J Malaysia 68(1): 64–66.
[PubMed](#) | [CrossRef](#) | [Others](#)
3. Lobo, F.A., Wagemakers, M., Absalom, A.R. "Anaesthesia for Awake Craniotomy." (2016) Br J Anaesth 116: 740–44.
[PubMed](#) | [CrossRef](#) | [Others](#)
4. Shirani, M., Alimohamadi, M., Moharari, R.S., et al. "Initial Experience with Brain Mapping under Awake Craniotomy for Resection of Insular Gliomas of the Dominant Hemisphere." (2016) Iranian J Neurosur 2: 10–14.
[PubMed](#) | [CrossRef](#) | [Others](#)
5. Grossman, R., Ram, Z. "Awake Craniotomy in Glioma Surgery." (2014) Eur Assoc Neurooncol Mag 4(1): 27-33.
[PubMed](#) | [CrossRef](#) | [Others](#)
6. Hervey-jumper, S.L., Li, J., Lau, D., et al. "Awake Craniotomy to Maximize Glioma Resection: Methods and Technical Nuances over a 27-Year Period." (2015) J Neurosurg 123(2): 325–339.
[PubMed](#) | [CrossRef](#) | [Others](#)
7. Nossek, E., Matot, I., Shahar, T., et al. "Failed Awake Craniotomy: A Retrospective Analysis in 424 Patients Undergoing Craniotomy for Brain Tumor." (2013) J Neurosurg 118(2): 243–49.
[PubMed](#) | [CrossRef](#) | [Others](#)
8. Mohamed, H.A., Arbab, M.A.R., Salim, A.D., et al. "Awake Craniotomy , an Unusual Indication." (2013) J Neurol Neurosci 4: 1–7.
[PubMed](#) | [CrossRef](#) | [Others](#)
9. Serletis, D., Bernstein, M. "Prospective Study of Awake Craniotomy Used Routinely and Nonselectively for Supratentorial Tumors." (2007) J Neurosurg 107(1): 1–6.
[PubMed](#) | [CrossRef](#) | [Others](#)
10. Goettel, N., Bharadwaj, S., Venkatraghavan, L., et al. "Dexmedetomidine vs Propofol-Remifentanyl Conscious Sedation for Awake Craniotomy: A Prospective Randomized Controlled Trial. (2016) Br J Anaesth 116(6): 811–21.
[PubMed](#) | [CrossRef](#) | [Others](#)
11. Jones, H., Smith, M. "Awake Craniotomy." Continuing Education in Anaesthesia Critical Care & Pain. (2004) Br J Anaesth 4(6): 189–192.
[PubMed](#) | [CrossRef](#) | [Others](#)
12. Piccioni, F., Fanzio, M. "Management of Anesthesia in Awake Craniotomy." (2008) Minerva Anestesiologica 74(7-8): 393–408.
[PubMed](#) | [CrossRef](#) | [Others](#)
13. Gonen, T., Grossman, R., Sitt, R., et al. "Tumor Location and IDH1 Mutation May Predict Intraoperative Seizures during Awake Craniotomy." (2014) J Neurosurg 121(5): 1133–1138.
[PubMed](#) | [CrossRef](#) | [Others](#)
14. Cormack, J.R., Costello, T.G. "Awake Craniotomy : Anaesthetic Guidelines and Recent Advances." (2005) Australasian Anaesthesia 77–83.
[PubMed](#) | [CrossRef](#) | [Others](#)
15. Joswig, H., Bratelj, D., Brunner, T., et al. "Awake Craniotomy: First-Year Experiences and Patient Perception." (2016) World Neurosurg 90: 588–596.
[PubMed](#) | [CrossRef](#) | [Others](#)
16. Khu, K.J., Doglietto, F., Radovanovic, I., et al. "Patients' Perceptions of Awake and Outpatient Craniotomy for Brain Tumor: A Qualitative Study." (2010) J Neurosurg 112(5): 1056–60.
[PubMed](#) | [CrossRef](#) | [Others](#)
17. Bajunaid, K.M., Ajlan, A.M. "Awake Craniotomy." (2015) Neurosciences 20(3): 248–52.
[PubMed](#) | [CrossRef](#) | [Others](#)
18. Osborn, I., Sebeo, J. Scalp Block During Craniotomy : A Classic Technique Revisited." (2010) J Neurosurg Anesthesiol 22(3): 187–94.
[PubMed](#) | [CrossRef](#) | [Others](#)
19. Rath, G.P., Mahajan, C., Bithal, P.K. "Anaesthesia for Awake Craniotomy." (2014) J Neuroanaesthesiol Critical Care 1: 173–77.
[PubMed](#) | [CrossRef](#) | [Others](#)
20. Blanshard, H.J., Chung, F., Manninen, P.H., et al. "Awake Craniotomy for Removal of Intracranial Tumor: Considerations for Early Discharge." (2001) Anesth Analg 92(1): 89–94.
[PubMed](#) | [CrossRef](#) | [Others](#)
21. Marigil, M., Bernstein, M. "Outpatient Neurosurgery in Neuro-Oncology." (2018) Neurosurg Focus 44(6): E19.
[PubMed](#) | [CrossRef](#) | [Others](#)
22. D'Antico, C., Hofer, A., Fassl, J., et al. "Case Report: Emergency Awake Craniotomy for Cerebral Abscess in a Patient with Unrepaired Cyanotic Congenital Heart Disease. (2017) F1000Research 5: 1-8.
[PubMed](#) | [CrossRef](#) | [Others](#)